

# PHILOSOPHICAL TRANSACTIONS.

---

I. *Further Inquiries as to the Structure, Development, and Function of the Liver.*  
By C. HANDFIELD JONES, M.D. Cantab., F.R.S. Assistant Physician to  
*St. Mary's Hospital.*

Received November 19, 1851,—Read January 17, 1852.

SINCE I presented to the Royal Society in 1847 the description which I have given of the structure of the liver, I have become acquainted with the researches of Professor RETZIUS, and of Dr. LEIDY, and have been favoured by M. NATALIS GUILLOT with a view of the preparations on which he grounds the opinions I noticed on that occasion.

Professor RETZIUS describes the hepatic ducts as forming close networks in the sheaths of GLISSON'S capsule, perilobular or alveolar networks; from which are given off minute lobular networks interwoven with the portal-hepatic plexuses, and constituting with them the substance of the lobules. These plexuses are described as consisting of anastomosing tubes which are formed of a basement or limitary membrane, like those of other glands, and in these tubes I presume Professor RETZIUS considers the hepatic cells to be lodged.

Dr. LEIDY'S account is very similar, at least as far as relates to the structure of the lobules; he figures the cells as lying within tubes, which have walls of basement membrane, and are two or two and a half times the diameter of the secreting cells.

In M. NATALIS GUILLOT'S preparations, the injection thrown in by the hepatic duct is seen lying in the interspaces of the capillary blood-plexus, and occupying the whole extent of the lobules. The view of these anatomists is in great measure accepted and confirmed by Dr. CARPENTER\*: he has satisfied himself that a system of canals prolonged from the bile ducts exists in each lobule, but is unable apparently to discover the basement membrane, which RETZIUS and LEIDY agree in describing. The testimony of MULLER, WEBER, and KRONENBERG is also to the same effect; they describe the hepatic ducts as commencing in very fine networks interlaced with the capillary networks between the portal and hepatic veins. And lastly, all the now

\* *Vide* Art. Secretion, Cyclop. of Anat. and Physiol.

mentioned authorities are but corroborators of the original description given by the founder of the anatomy of the liver, Mr. KIERNAN, so that one can scarce withhold assent from the doctrine, that a "lobular biliary plexus" really exists\*.

To advance a contrary opinion in the face of the testimony of so many and so eminent authorities, can hardly be judged other than presumptuous; yet if it appear that the ascertaining of truth is my sole object I shall not fear this censure, as well knowing that candid minds are glad to confront their own views with all possible objections, which serve as tests to detect the alloy of error, and to bring forth into clearer show the lustre of the real gold of truth.

I will mention first two results I have obtained by the method of injection, which go to confirm the views of those who maintain the existence of a lobular biliary plexus, and are, therefore, opposed to that which I have supported. In reading the description given by chemists of the mode of obtaining the acids of the bile, the cholic, and the choleic, it occurred to me, that the same reagent, the acetate of lead, might be employed to produce a precipitate with the bile while still contained in the ducts.

I tried this first with a Guinea Pig, injecting the ductus com. choled., immediately after the animal had been killed, with a saturated solution of the salt above mentioned. This produced a most abundant precipitate in the gall-bladder, and along the ducts, even to those of extreme minuteness, rendering them visible to the naked eye as ramifying white lines or streaks. In several parts there was seen springing from the sides of ducts running in fissures or small portal canals, a minute plexus consisting apparently of short straight vessels, uniting at nearly right angles with each other. When very thin slices of parts presenting this appearance were minutely examined, it was manifest that these vessels exactly occupied the intercellular spaces; they had no membranous walls, and seemed to consist solely of injection forced in between the cells. Their diameter was very uniform  $\frac{1}{10,000}$ th of an inch, and the side of the meshes exactly equalled that of the cells, about  $\frac{1}{1000}$ th of an inch. They originated directly from the ducts of fissures or canals, and not from any such network as Professor RETZIUS describes. This appearance of a plexus was very partial, it occurred only in certain spots, and not, as it appeared to me, in those parts where the ducts were best injected; but was seen as a border of varying width along those portal canals where extravasation had manifestly occurred. I repeated this experiment with the liver of the Sheep, and obtained a result which appeared very striking. The lobules, where the injection had penetrated, presented in their whole extent the appearance of a plexus. This plexus was very different in its aspect to the partial one obtained by injection of the Guinea Pig's liver; it consisted not so much of distinct vessels, but of spots, patches, and very fine streaks, coalescing irregularly together. I am inclined to consider the result in both these cases as produced by the action of the acetate of lead upon the albuminous plasma lying between the cells;

\* KÖLLIKER, however, denies the existence of a biliary plexus, and describes the ducts to terminate nearly in the same way that I do.

this agent, when added directly to a portion of parenchyma, produced no marked effect on the cells, rendering them only somewhat more granular, but coagulated a considerable quantity of the free interposed material.

Having described these two results, which, though quite capable, as I conceive, of being otherwise interpreted, appear to support the opinion of there being a lobular biliary plexus, either containing and enclosing the cells in its passages, or interposing its tubes between them, I now proceed to detail those observations which I have recently made, and which after candid consideration do still confirm me in the opinions I formerly expressed, and also throw some light on the mode in which the efferent mechanism may be conceived to perform its function.

The class of Fishes I have found, as before, most easy of examination, and most productive of results, and I would ask inquirers into the subject to direct their attention carefully to these examples. My later dissections have confirmed entirely the description given in my last paper; they show the ducts running a long course with comparatively little branching through the parenchyma, encrusted by it on every side, and terminating without forming any such connection with it as to envelope and surround it. Often the ultimate branches appear as tracts of finely granulous or amorphous matter, in which, when it is broken up, delicate nuclei are discerned: this is perhaps the most common condition, but there are two others which I have most unquestionably observed, and which *quoad* the physiological action of the parts are of great interest. In one of these, the least common, the nuclei are not obscured by the granulous matter, but are distinctly visible, as I figured them in my last paper from the liver of the Perch; they seem to constitute the chief part of the wall of the ductule, and lie close together in a scanty amount of granulous basis substance. This condition, unusual in Fishes, is ordinary in Mammalia; of its import we shall subsequently attempt to give some interpretation. In the other condition, the ducts, not only the terminal, but even the smaller trunks, are *filled* with a pellucid opaline material, in which are imbedded vesicles containing a fluid of the same aspect; often the vesicles are exceedingly numerous, and seem to replace the opaline material; it may indeed be said that the two exist in inverse ratio, and that the one is developed from the other. It seems most probable that the fluid in the interior of the vesicles is bile, and that by their dissolution it is set free in the efferent passage.

A very frequent appearance is, that in the interior of ducts the outlines of vesicles are discerned more or less distinctly in various parts amid translucent free material. The size of the vesicles varies a good deal, from  $\frac{1}{333}$ rd of an inch to  $\frac{1}{1000}$ th of an inch; they seem of exceeding delicacy, but resist sufficiently to alter each other's shape by mutual pressure, and to float about in the water for a short time after they have escaped from the duct. I have called them vesicles, as they do not commonly appear to contain nuclei; but in one instance I found that nuclei did exist in their interior, so that they may sometimes no doubt attain the rank of cells.

An important point to be noticed with regard to the ultimate and penultimate ducts is, that they appear to be *filled* with their epithelium; the central passage must

be extremely small, and cannot be actually discerned: this surely is not the condition of a mere channel of passage, a mere outlet for an already elaborated fluid; it surely betokens an active process of attraction, and probably chemical transformation to be going on.

The truth of this remark will be more apparent if we compare the condition of the epithelium of the ultimate or elaborating ducts with that of the large trunks; in the former it has the characters we have just described; in the latter it consists of a simple pavement of short columnar particles; the one is in the condition of the ureter or any simple mucous surface, the other in that of the deeper parts of the gastric or renal tubule.

I subjoin here the details of some examinations I have made in this class of animals, believing that I cannot in any better way convey an idea of the various appearances observed. In a Pike (*Esox lucius*), to whom I had given a dose of calomel, there was observed a peculiar condition of the ducts which seems worth noticing, although there was no reason to regard it as in any way produced by the drug. Many of the larger ducts were obstructed by a concrete deposit in their interior, which, viewed by direct light, was of a glistening white, and probably consisted of cholesterine or some bile-derived matter. At the obstructed parts the duct was considerably narrowed, while beyond it in the direction of ramification it was greatly dilated, sometimes to more than twice its natural magnitude; the distended part forming a pouch of somewhat globular form, into which small absorbing ducts opened; these must doubtless have existed, though they seemed in some cases to be more or less obliterated. The wall of the dilated part was greatly thickened, chiefly by an increase of its fibrous investment; within this a homogeneous tunic was distinctly discernible, supporting a layer of epithelium, which was, I believe, of secreting function, and not a mere lining. The fluid contained in the dilated part was in some instances of a decided bilious colour, which probably depended on its having become concentrated by being retained in the canal longer than usual. The obstructions in the ducts had occasioned no noticeable change in the parenchyma; it was tested for sugar by TROMMER'S method, and gave distinct evidence that this was present.

About the middle of February I examined a Roach (*Leuciscus rutilus*) very full of ova, the parenchyma of the liver was of a pale red tint and semitranslucent; it consisted of nuclei, granular matter, and multitudes of delicate semitransparent vesicles packed closely together; one or two tablets of cholesterine, and some biliary deposits were observed in it.

One part of this liver formed a long thin tongue, and this viewed without being cut exhibited a beautiful capillary network perfectly injected with blood; the vessels formed long narrow meshes; and it was especially observable that, while there was scarcely any oil to be seen in other parts of the parenchyma, there were little groups of small oil-drops seated at intervals all along the sides of the vessels, as if it had just exuded from them. The ducts, when dissected out, were seen most perfectly; all the elaborating ones were crowded with delicate pellucid vesicles, varying a good deal in size,

and lying together with nuclei imbedded in amorphous matter; similar vesicles and more distinct nuclei were seen in the larger ducts up to a diameter of  $\frac{1}{3}\frac{1}{8}\frac{1}{4}$ th of an inch; some biliary deposits were seen adhering to the exterior of the ducts, which in this instance were not dilated.

About the same time I dissected another Roach whose abdomen contained but little roe, and who had been dosed, fifteen hours before death, with two grains of blue pill.

The spleen contained several groups of yellow corpuscles; some of the larger were surrounded by a homogeneous envelope; they consisted of various-sized corpuscles of about the diameter of blood-globules, but more spherical and more opaque, as well as more brightly and differently coloured. Coloured corpuscles were sometimes seen quite alone, sometimes a very few together; such were not surrounded by envelopes.

The liver was of the buff-yellow colour, which indicates a fatty condition; its parenchyma was loaded with oil, which was in the state of small drops that became detached and floated freely about in the field of view; I satisfied myself of the existence of the pellucid vesicles that were so numerous in the former, but they were not present in nearly so great numbers; the parenchymal substance presented the appearance of imperfectly formed celloid particles coalescing together in a plexiform manner; they were surrounded and enveloped in oily matter. In some parts small biliary deposits were also observed.

On dissecting the ducts out, I found some of the trunks extraordinarily dilated into great pouches; the smaller branches, and especially those nearly terminal, were not enlarged, or not much; but they and all the ducts, even the trunks, were stuffed with their epithelium, which was at first scarcely discernible, the tubes appearing as if filled with a pellucid matter; but when one was ruptured and the epithelial contents escaped, the vesicles, nuclei and amorphous matter came clearly into view.

On examining closely the large ducts, especially after steeping them in solution of bichloride of mercury, it was well seen how their epithelium had encroached on their cavity, so as in some parts to have closed the canal completely; this obstruction had doubtless occasioned the dilatation of the ducts into pouches, which may also have been promoted by the inordinate growth of the epithelium in those parts. The dilatation of the ducts was not confined to those now described; many of the smaller were also affected, so that branches traced in the direction of ramification actually enlarged instead of diminishing, and this manifestly depended on their own stuffing, and the obstruction towards the outlet. In some ducts the vesicles were very apparent, crowded together in groups; in others there was scarce anything to be seen but an amorphous and fluid matter. Neither this liver nor that of the preceding yielded me any evidence of the presence of sugar.

A third Roach was dosed with  $1\frac{1}{2}$  grain of blue pill twice, an interval of seventeen hours being allowed to elapse between the doses; it was killed sixteen hours after the last. It contained large masses of ova. The liver was pale, semitranslucent, and contained a good deal of blood in its vessels; its parenchyma consisted of nuclei, granulo-amorphous matter, and very delicate granular globules; there was very little oil, and

not any biliary deposits were seen. The gall-bladder was very full of bile. The ducts dissected out appeared occasionally distended, but to a much less extent than in the preceding instance; the epithelium in the larger ones consisted of columnar particles, which viewed *in situ* gave a mosaic or pavement-like appearance; in those of next size the epithelium was in great part vesicular; and in those of smallest size it chiefly consisted of nuclei and amorphous matter, with a few incipient vesicles. In several of the ducts the canal was very much narrowed by the epithelial growth.

These details, though rather minute, are not, I think, devoid of interest, especially as illustrating the actively growing nature of the epithelium of the ducts. With regard to the condition of the parenchyma generally I have nothing to add to my former observations, except that I have usually noticed that when the ova are considerably developed, and form large masses occupying a great space in the abdomen, the quantity of oil in the liver is greatly diminished; it seems to be diverted from its usual place of deposit, and appropriated to the formation of the growing structures.

#### *Development in Fishes.*

I now proceed to describe the development of the liver in this class, in which it is observed under very favourable circumstances, as the stages succeed each other slowly, and the transparency of the tissues enables the observer to conduct his examination with little injury to the specimen. In a young Perch (*Perca fluviatilis*), which had recently quitted the ovum, and in which the circulation was distinctly visible, I found the vitelline sac attached to the body, but not included by abdominal walls; there was no intestine yet formed, nor any trace of liver. In the vitelline sac there was seen a smaller one lying near the anterior extremity just behind the heart; this contained a more highly refracting matter than that in the larger vitelline cavity. The next day I observed that the heart was covered in by a strong membrane which passed over the yolk-sac, and was continuous with the inferior vertical fin, and doubtless with the sides of the body, thus closing in the abdominal cavity.

An intestinal tube was now formed, and an oral cavity, but the intestine did not communicate with it, nor had it any anal outlet. By the morning of the next day the intestine had extended quite to the throat, and was enlarged into a fusiform dilatation corresponding to the stomach, while a narrow space intervened between it and the vertebral column. By the evening of the same day the continuity of the intestine as œsophagus into the throat, and the cavity of the mouth was most distinct. I observed a short blind offset passing backwards and upwards towards the vertebral column from the stomachal dilatation; this was evidently the rudiment of the air-bladder. A day later the plicæ of the intestine had begun to appear; its walls were very thick, there was no trace to be seen of liver, or of renal glands. Peristaltic movements were observed in the intestine twenty-four hours later; the duct of the air-bladder was now of pretty good length, but scarcely appeared to be hollow.

Two days from this time the intestine was sufficiently consistent to admit of being detached; its surface was still more plicated; its posterior fourth was separated from

the anterior portion by a kind of annular constriction, thus marking off the future large intestine: the walls presented some appearance of developing muscular fibre.

Three days later the cardiac orifice of the stomach presented a more marked constriction, separating it from the œsophagus; no liver nor kidneys were yet formed. I observed at this time that the black pigment was deposited directly as such, constituting globules and streaks of various size, and not previously elaborated and gradually formed in cells. The next morning, that is ten days from the date of the first observation, I observed a mass at the anterior part of the abdomen, extending on a level with the anterior part of the yolk-sac to some distance behind it; this was doubtless the rudiment of the liver; it consisted of granulo-amorphous matter, and was traversed by ramifications of a vessel which spread itself over the yolk-sac; this vessel was a branch given off from the cardinal vein near the anus; it ran along the lower border of the intestine, and after ramifying on the yolk-sac and on the liver, joined a vein entering the heart. A rudiment of the gall-bladder, in the form of a small transparent vesicle, was also observed; the lower end of this appeared to dip down towards the intestine.

On the succeeding day I noted that the parenchymatous mass of the liver was quite distinct, and that the transparent vesicle, the future gall-bladder, adhering to it, had enlarged, but without having yet formed any communication with the intestine. I dissected the intestine out, and saw clearly that there was no protruding of its parietes as if the liver were a development from it. The constriction separating the small and the large intestine was very marked and the appearance of the two very different, the former being thrown into many folds, the latter being more smooth. On the evening of this day I observed the liver having the same shape as in the adult fish, the anterior border being notched; it was traversed by a pretty close plexus of capillaries, and contained the remains of the small yolk; it consisted of granulous and oily matter imbedding delicate vesicular cells. Two days later the parenchyma of the liver had nearly the same aspect; its cells were probably more numerous; they varied in diameter  $\frac{1}{3000-666}$ th of an inch, and were imbedded in oily and granulous matter. The gall-bladder was still a transparent vesicle, in diameter  $=\frac{1}{143}$ rd of an inch, formed by a homogeneous tunic and having some traces of a lining epithelium; its shape was somewhat pyriform, the small end being directed upwards or anteriorly. It was distended by a transparent fluid, which as yet had no outlet. Two days after I noted that the yolk-sac imbedded in the parenchyma of the liver had become very small, and that the gall-bladder was elongated and tended downwards and backwards towards the intestine. The succeeding day the narrow extremity of the gall-bladder was still more elongated; it tended still more downward, and adhered by its apex to the stomach.

After having carried my observations thus far my stock of young fish died, and I was unable in consequence to follow the further progress of development regularly, but after the lapse of about six weeks I procured some minute fish very similar to those I had before been observing. The result of my examination of these was as

follows. The liver appeared as a small grayish mass, consisting of delicate vesicular transparent cells, mingled with granulous and oily matter, not in great abundance. The gall-bladder was large, distinct, transparent, full of a colourless fluid, and lined by a distinct epithelium; it had a short duct communicating with the intestinal canal, from which an offset turned up to the mass of the liver; this proceeded but a little way, and terminated by forming a small tract of nuclear particles. The resemblance between the structures observed in these young fish and those whose development I have traced above was so close, that I feel quite justified in concluding that the former presented the ultimate stage of the developmental process, and therefore I venture to offer the following summary as descriptive of the formation of the liver and its excretory apparatus in Fishes.

(1.) The intestine is formed before there is any trace of liver.

(2.) The parenchyma of the liver and a vesicle, the rudiment of the gall-bladder, are first formed; the small yolk mass lies in the substance of the liver.

(3.) The gall-bladder assumes a pyriform shape; its narrow end approaches the intestine and opens into it, while from a part of its extent hepatic ducts are developed that extend into the liver.

(4.) The contents of the gall-bladder at first are not bile, but probably a weakly albuminous fluid; this continues to be the case for some time after the parenchyma of the liver is completely formed.

In my examination of the livers of Reptiles I have been more successful than formerly, and entertain no doubt of their being constructed exactly after the same plan as those of fish. The parenchyma in the Common Frog (*Rana temporaria*) presents no appearance of any lobular division; it is often of very dark colour, owing to the presence of a black pigmentary matter; it consists of delicate, large, feebly-formed nucleated cells, which have no well-marked envelope, and almost appear like masses of granulo-amorphous substance; they are infiltrated with oil-drops, but present no bilious tint. There are also numerous free nuclei, and much diffused granular and oily matter as well as black pigmentary, which is in the molecular condition, and exhibits the peculiar to and fro motion. A considerable quantity of the black matter is in the form of spherical or oval corpuscles, which I described in my previous paper, and which have often a red or deep yellow tint. I supposed them at that time to be biliary concretions, but further inquiry has convinced me that such is not their nature, and that they are what I have termed them above, pigmentary formations. They are scarcely affected by the strongest reagents; liquor ammoniæ, liquor potassæ, sulphuric, nitric and muriatic acids leave them almost unaltered. On comparing them with the coloured corpuscles found in the spleen they appear quite identical, and I have little doubt are truly so; both I am inclined to think are pigmentary deposits, not necessarily derived from decomposing blood-globules. They do not occur in the kidneys, and are quite distinct from the ordinary ramifying pigment cells seen in other parts. I believe them to be a peculiar form of organic matter, rich in carbon, which not being eliminated from the blood in consequence of



the feeble grade of respiratory action, settles down as a deposit in these two parts, where accumulation of the blood and retardation of its current, one or both, frequently and almost naturally occur. In a Common Snake (*Coluber natrix*) I found the parenchyma consisting of abundant soft granulous and oily matter, with granular nuclei, faintly formed granular globules and cells; the latter were small, not numerous, and might easily have been overlooked. There were no pigmentary globules in this liver, but in one part of the parenchyma there was a deposit of bile tinging the granular matter, so that that part contrasted manifestly with the surrounding: there was also everywhere a considerable quantity of concrete solid fatty matter, sometimes of coarse crystalline aspect. The ducts in this instance were well seen ramifying on the coats of the vessels; many of them exhibited their tube of limentary membrane filled, and even apparently bulged by a soft granulous substance, which obscured the nuclei imbedded in it, and was mingled with a few minute oil-drops diffused through its mass. The most minute branches appeared to cease gradually, the basement membrane becoming at last indiscernible, and the structure then resembling a minute cylinder of granulous substance. Some of the larger ducts had more transparent contents, in which here and there small vesicles were seen.

In the Frog I have been able to examine the ducts very thoroughly; the smallest ones are I think for the most part like those in the Snake, small cylinders of granulous substance imbedding nuclei, and not usually containing vesicles; those of a somewhat larger size (but having I doubt not the same elaborating function) are usually full of pellucid contents, in which the outlines of exceedingly delicate vesicles, varying from  $\frac{1}{1666}$ th to  $\frac{1}{2500}$ th of an inch, are more or less plainly discernible. These vesicles should probably be termed cells, as on addition of nitric acid a number of nuclei are brought into view, which appear to be situate in their interior. It is remarkable how the duct tubes are filled with the vesicular and granulous epithelium; they have exactly the same appearance as their homologues in Fishes, and suggest the same ideas as to their function. In one frog the description now given exactly applied to the ducts of one lobe of the liver, while those of the other were in a very different state; instead of having pellucid contents, they presented a thick epithelial lining of rather coarse granular matter containing nuclei, and stained deeply in various parts with biliary matter. The aspect of this epithelium conveyed to the mind the idea of arrested action; it contrasted most forcibly with the delicate soft-looking granulous or pellucid epithelium of the ducts in the other part; this had the aspect of material rapidly changing into the fluid secretion, that of a stiff inert mass, whose vital changes were well nigh suspended. Connecting with this altered condition of the epithelium the manifest biliary accumulation and retardation in the ducts, the above interpretation will not appear I trust too fanciful. With the alteration in the condition of the ducts, there coexisted also a notable difference in that of the parenchyma; its cells were much more strongly formed, their nuclei and envelopes more apparent, their contents coarsely granular, and containing less oil than in the unaffected part. The

ducts were clearly seen in this instance to pursue a long course with very little ramification; one branch I traced for  $\frac{1}{67}$ th of an inch without observing any branch given off from it, or scarce any diminution in its diameter.

*Development in Reptiles.*

IN REICHERT'S description of the development of the embryo of the Frog (von MULLER'S Physiology), it is stated that the anterior part of the mass of yolk contained in the cavity of the abdomen isolates itself from the rest of that substance, and becomes an independent body; which constitutes the rudimentary mass from which the liver and pancreas are subsequently formed. This I think I have also observed, or at least that as soon as the yolk mass begins to take the form of an intestinal tube a portion of it remains separate, constituting two masses, a larger and a smaller, which lie one on each side of the nascent intestine. When development had advanced a little further, and the intestine was manifestly formed, I found the parenchyma of the liver lying close in contact with it, and also a small vesicle adhering to the mass of the liver, which was certainly the rudiment of the gall-bladder. The future liver consisted of multitudes of large vesicular nuclei lying imbedded in oily matter, and the whole mass was surrounded by an investing homogeneous tunic. The gall-bladder in its earliest appearance was simply a spherical mass of similar constitution to that of the liver; subsequently it presented a distinct membranous wall lined inside by a close layer of large vesicular nuclei, the interspaces between which were occupied by oil-drops. It assumed very soon more or less of a pyriform shape, and became connected with a narrow tract stretching down to the intestine which clearly represented the cystic duct; this tract consisted of similar formative substance to that composing the liver and the gall-bladder; from it in a more advanced stage offsets were developed having the same constitution, and extending into the substance of the liver; these were beyond doubt rudimentary hepatic ducts. In one instance, where the gall-bladder existed, but was certainly not connected by a duct with the intestine, I saw lying by its side a short tract consisting of similar material, which was partially divided at its peripheral extremity; this seemed to be an early rudiment of an hepatic duct. The rudimentary ducts appeared to me to be solid tracts; I could not at this period detect a cavity in the interior; subsequently they become invested with a homogeneous tunic on their exterior, and the vesicular nuclei arrange themselves in the form of an epithelial lining, the interspaces between the nuclei being occupied with oily matter. Both in the gall-bladder and in the ducts this oily matter gradually disappears; the epithelium of the former comes to present the ordinary form of a pavement, while that of the common duct *developes cilia* which are seen in vigorous action, exciting a current downward from the liver to the intestine. I do not know exactly how long this ciliary action continues to be present in the hepatic duct; I have observed it for about a month from the date of its first appearance. As development advances the oily matter in the parenchyma of the liver diminishes, and

is replaced by granulous ; pigment granules at the same time are deposited upon and in the vesicular nuclei, and thus those yellow and brown-coloured masses are formed which are so apparent in the liver of the adult animal. The gall-bladder for some time contains only a transparent fluid, which is coagulated in a marked manner by nitric acid, and is therefore probably only a solution of albumen ; after a time the fluid in this receptacle has a biliary tinge, and then is not coagulated by the action of nitric acid. This was at least the case in two instances, though in another at a still later period the acid produced a precipitate which however may have been only mucus.

The general conclusions respecting the development of the liver in the Frog may be stated as follows :—

(1.) That a portion of the common formative yolk substance contained in the abdomen is set apart for the development of the liver.

(2.) That this occurs at about the same time when the intestine begins to be formed, so that the liver is not in any way derived from the intestine.

(3.) That the first rudiment of the efferent apparatus is the gall-bladder, and that the ducts are subsequently formed.

(4.) That a cystic duct is first formed, connecting the gall-bladder with the intestine, and that hepatic ducts are subsequently developed.

(5.) That these ducts are at first solid tracts, and as well as the gall-bladder primarily consist of similar formative substance to that which composes the liver.

I may add here that I have seen very distinctly the ciliary motion on the outer tegumentary surface of tadpoles as described by Dr. GAIRDNER ; my observations were made several months before I had the pleasure of reading his description of it.

I may remark that I have obtained some very satisfactory views of the minute biliary ducts in the liver of a Rook (*Corvus*) by stripping out branches of the portal vein and washing away the parenchyma. The ducts were then seen here and there lying upon the homogeneous membrane of the vein-branches. Their condition was essentially and closely similar to that described in my former paper.

#### *Development in Birds.*

Since the publication of the account I gave in my previous paper of the development of the liver in the Chick, I have twice repeated my observations, and have found the views I advanced in the main correct. I think, however, it may be worth while to review some stages of the progress which it is important to investigate thoroughly.

The formation of the intestine takes place by the constriction of the central transparent portion of the germinal membrane ; this seems to me to be a homogeneous membranous expanse, not composed of cells, and covered only with oil-drops, while the rest of the germinal membrane with which it is continuous is covered by adhe-

ring yolk-cells, and overspread with ramifications of the omphalo-meseraic vessels. When the constriction of the germinal membrane takes place, two tracts of oily matter appear, one passing forwards and the other backwards from the constricted part, where they are continuous with each other. The margins of these tracts are quite even, and soon become invested with a homogeneous membrane, but at first I doubt if this is actually present; in a chick at the seventy-seventh hour of incubation, the transparent membrane of the vitelline duct appeared to me to lose itself upon the tracts of oily matter. The upper margin of the vitelline duct and of the oily tracts forms at first nearly a straight line, which is separated by a considerable space from the vertebral column, one-half to one-third of this space being occupied by the Wolfian bodies. The posterior tract ceases near the caudal extremity; it is, I think, rather thicker but shorter than the anterior. This, in the earliest periods after passing forward with a slight curve, is lost just as it reaches a quantity of blastema situated close behind the heart. This blastema is the rudiment of the parenchyma of the liver; it does not consist of oily matter like that of the intestine, but of a less opaque and more granular substance. As development advances the anterior tract continues to extend; it passes forwards and upwards above and behind the liver, and was traced on one occasion, though becoming more faint, as far as the last branchial fissure; a slight dilatation at one part of its course marks the future stomach, and from near the same part two offsets are given off, one of which runs upon the liver, the other towards the vertebral column. Both oily tracts and the offsets just mentioned are solid; they are to be regarded, I think, as a peculiar deposit of formative matter intended for the formation of particular structures; their appearance and mode of development seem to me by no means consonant with the view that the intestinal cavity is simply a part shut off from the general yolk cavity. In fact, the intestine, as has been said, is not at first a cavity but a solid tract of formative matter, and in this respect is analogous to the embryonic condition of other organs (so far as I can determine), which always seem to arise from a shapeless blastema deposited in one spot. The offset to the liver is more distinct sometimes than at others; it is most marked about the sixth day, but always may be distinguished as a small eminence of opaque oily matter in the side of the intestine, until the cystic and hepatic ducts are fully formed and have united with the intestine *at that spot*. The existence of this eminence is certainly very remarkable; it may be well to give it a name and call it the *colliculus*; I do not see that its import at present can be at all explained; nor could we indeed expect this, unless we could obtain some clue to the comprehension of the mysterious principle by which the process of development is governed. I cannot see any ground for the statement that the liver is developed by the protrusion of the walls of the intestinal canal; it certainly appears at a very early period as a parenchymatous mass of blastema; and even if one could grant that this blastema originated in any way from the anterior oily tract which passes close to it, still it remains, according to my observation, perfectly unquestionable, that after the in-

testine and stomach are formed up to about the ninth or tenth day, the mass of the liver has no connection by ducts with the intestine.

In one instance I obtained a very good view of the developing hepatic duct as it approached the liver; it was formed in a tract of cell substance, which served as a blastema, and was invested on its margin by some fibrous tissue; in this the channel of the duct was excavated, which was lined by a distinct homogeneous membrane, and invested by a delicate transparent epithelium. Towards the hepatic extremity the cavity became less marked, its margin indistinct, and the homogeneous tunic less perceptible; but I satisfied myself, by very careful examination, that the duct-channel terminated by a cul-de-sac, while the blastemous tract, as yet unexcavated, stretched on much further.

In the parenchyma of the liver, just at the beginning of the fifth day, the formation of vessels and blood was very well seen; several groups of blood-globules lay in short channels provided with a fine homogeneous lining; these were oval or more elongated; they did not appear to coalesce, but were manifestly tending to such an arrangement, which a few hours later had actually occurred.

I saw no cells throwing out filamentary processes, such as KÖLLIKER has described; the channels containing the blood-globules were spaces excavated in the blastematous mass; their homogeneous walls I believe to be produced secondarily, and their coalescence to be effected by a simple extension of their cavity.

About the eleventh day I found the parenchyma of the liver consisting of nuclei, cells, amorphous and abundant oily matter; here and there in the midst of the substance there were seen small bright yellow particles, which were doubtless biliary matter; the gall-bladder also was full of green bile, the presence of which, as there was no trace of cysto-hepatic ducts to be seen, I cannot satisfactorily explain; it does not appear to me, however, an idea to be altogether rejected, that before the hepatic ducts are fully developed, and have begun to eliminate bile in the parenchyma, their function should for a time be performed by the epithelium of the gall-bladder, which lies in close contact almost imbedded in the mass of the liver: the fact, at any rate, is, that the gall-bladder contains bile, when there is not a trace of it in the ducts, and when their development is yet incomplete.

The development of the pancreas seems to be very similar in its mode to that of the liver, and the same plan will, I believe, be found to be followed in the formation of all glands. The organ consists at first of blastematous matter, imbedding nuclei and myriads of granular globules, which are clustered over with oily molecules. The sides of the mass are even, and it presents no trace of the ultimate glandular vesicles, which are so characteristic of its adult condition. About the same time that the ducts of the liver appear, those of the pancreas begin to be developed; they are not formed by a protrusion from the intestine, but rather seem to develop themselves on the spot where they are to exist. This at least is the case with the main trunks; the smaller branches are no doubt formed by an extension of the cavities of the larger ones

It must be sufficiently apparent how essentially similar the development of the liver and its apparatus of efferent ducts is found to be in the three lower vertebrate classes. Hitherto I have not been able to pursue the examination in Mammalia; and though I am aware that BISCHOFF'S account of it in this class is in accordance with the view of its being a protrusion from the intestine, yet I must remark that the process, as being conducted more slowly in the lower classes, is more favourable for correct observation, and that it seems unlike the known unity of scheme which characterizes the works of Nature, to find an essential difference in one class from that which prevails in the three others.

I have little to add to the anatomical account I previously gave of the condition of the liver in Mammalia; I have studied it recently more particularly with a view to the elucidation of its function, and will now only touch on those points which bear upon this matter. One most important question to determine positively is where the bile is in the healthy state necessarily formed; whether in the cells of the parenchyma, or in the ultimate hepatic ducts. The prevalent opinion among physiologists certainly is that the bile is actually and necessarily formed in the hepatic cells; they are considered homologous to those of the renal tubuli, and on account of this homology and a certain not very manifest yellowish tint, it is usually held that the bile is primarily formed in them, and liberated by their dehiscence in the cavity of the duct. From this opinion, which I long held unquestioningly, and to which I have often referred, observation alone inclines me in some measure to dissent. I have scrutinized numerous specimens of the livers of our ordinary domestic animals with a view to determine this point, and still cannot convince myself that bile is present in the parenchymal cells as a *normal* and *necessary* condition. If present, it ought not to be very difficult of detection, seeing that it is a coloured fluid, and that the cell which contains it is in this class generally provided with a distinct envelope: it ought, in fact, to be as apparent, or nearly so, as it is in the cells of the follicular livers of Mollusca. But this is not the case; according to my observation the cells commonly appear as pale granulous nucleated particles, with a more or less distinct limiting envelope, and presenting a few or perhaps numerous and large oil-drops amid the soft albuminous mass. Not unfrequently a distinct yellow fluid is seen infiltrating the granulous contents, or several yellow highly refracting drops are observed in the same situation; this indicates of course that bile is present in such particles, but they are seldom seen except when the liver is in a state of so-called biliary congestion. This condition is consequently most often observed in human livers. The cells, when massed together and viewed by transmitted light, very commonly, perhaps always, produce a kind of reddish yellow tint; but this seems to me to differ decidedly from the yellow tint of bile, and to be probably dependent on some diffused hematin tinging the cells, or on some modification which the light has undergone by unequal refraction in its passage through the mass; at any rate I could not, were I advocating the opposite opinion, rely on it for a moment as sufficient evidence of the presence of

bile in the cells. In some instances of healthy livers in animals, as in the Mole (*Talpa europæa*), the Hare (*Lepus timidus*), and the Squirrel (*Sciurus*), and also in others, I have noted the presence of biliary matter in the cells; nor do I doubt in the least the possibility of its being frequently so found, only it seems to me that evidence is wanting to show that this condition is constant and essential. I have often tried the effect of adding nitric acid to the cells, but I do not think that I have thereby obtained any more decisive evidence regarding the point in question; this reagent makes the cells more opaque, contracts them, renders their envelopes more marked, and their contents more granular, but does not impart a more positive biliary tint. I think as soon as a real yellow tint exists the eye will judge of it much more satisfactorily when the cells are in their natural state, than when they are shrunk and entangled amid granular films of coagulated plasma.

Not wishing to rely solely on my own observations, I wrote to three of the most eminent physiologists in London, requesting they would inform me of their views on the matter; they kindly replied to my inquiries, and permit me to subjoin their replies. Mr. BOWMAN'S communication is as follows:—"My notion of the matter you refer to is shortly this, that the bile does exist in those hepatic cells that lie nearest to the surface of the lobules, *i. e.* to the portal surface where the ducts commence; not that those cells contain nothing but bile, but that bile comes out of them, either by their rupture and deliquescence, or while they lie *in situ*, undergoing only such slow degeneration as is common to the elements of most or all tissues. That the cells lie in series extending from the hepatic venous to the portal venous surface, and that there is an onward march of the cells from the former to the latter; those near the former being immature, and those near the latter mature; that the bile is gradually elaborated by the agency of all, but probably chiefly by those situated nearest the portal surface. The yellow and brown hepatic substances are the immature and mature hepatic cells respectively. The congestions of KIERNAN seem to me to depend on the bulk of these cells respectively, allowing the capillaries which flow through them to hold more or less blood after death. Many of the morbid appearances of the liver are, in my opinion, dependent on diseased conditions of one end of the series of the hepatic cells (the hepatic venous or the portal), to the exclusion of, or in a different way or degree than that other." This view of Mr. BOWMAN'S is nearly the same as that I proposed in my first paper on the Secretary Apparatus of the Liver, published in the Philosophical Transactions; only that I believed the cells not to progress ("march") outwards from the centre, but that the bile was transmitted from cell to cell in order throughout a series. What led me especially to doubt of the truth of this opinion, was simply that in the majority of livers I saw oil only, and not bile in the cells. If oil be regarded as the secretion of the hepatic cells instead of bile, the view of Mr. BOWMAN would receive very strong support, for oil does accumulate in many instances, especially in Sheep's and in certain Human

livers\*, in a very remarkable manner in the marginal cells of the lobules, so as to form a complete opaque border to them; and these same oil-laden cells are seen at times dehiscing, and apparently discharging their contents into the fissure.

But oil is not bile, and therefore this very case becomes an objection to the view of Mr. BOWMAN; for if bile is perfected in the marginal cells, it ought to be manifest and preponderating there, which in these instances, and indeed generally, is not, as far as I have seen, the case. Another condition, which I have several times observed in Human livers not seriously diseased, also appears to speak counter to the view of bile being perfected in the marginal cells of the lobules. In these, for instance, when a transverse section had been made, the central part of the lobules was seen of a distinct yellow tint, the cells manifestly containing bile; this colour shaded off towards the margin, and ceased some distance from thence, while the marginal cells themselves, for a depth of two or three in the central direction, were the seat of considerable *oily* accumulation. This could hardly have occurred if the perfection of bile by the marginal cells were a necessary step in the process†.

Though not at all essential, though I believe the ducts often form bile when none exists in the marginal cells, still there does appear to be a peculiar tendency in the cells in this situation to fill themselves with biliary matter. I have seen bile in the marginal zone of cells when all the rest of the lobules was in a state of complete degeneration; I have observed in the liver of an animal, to whom calomel had been given, bile, though present elsewhere, yet most abundant on the margins of the lobules; I have seen a similar state, accumulation of bile in the marginal cells, occasionally in Human livers; and lastly, I have often found biliary deposits adhering to the ducts in the oily livers of fish, occupying thus an analogous situation to that of the bile in the preceding instances.

The circumstance that oil in many cases accumulates particularly in the marginal zone of cells, seems to me most probably accounted for by the relation of this part to the circulating blood. These marginal cells are, in fact, the first which are exposed to the stream of portal blood as it enters the lobular capillary plexus; they consequently obtain most abundantly the oily matter therein contained, and store it up in their cavities; this, I think, is a more probable view, according to our present knowledge of the habits of cells, than to suppose that the oil is transmitted from the

\* *Vide* Report of the Pathological Society, 1846, 1847, p. 105.

† When a liver presents the "nutmeg appearance" in the most marked manner, the following is commonly found to be the condition of the structure. There is fatty degeneration of the marginal zone of the lobules, which is thereby rendered quite pale; while the central part, occupying perhaps rather more than a half, is uniformly saturated by a deep venous congestion. The cells in this part are in great measure destroyed, reduced to a granular detritus, and the remaining ones are converted into spherical masses of orange pigment. The sanguine congestion and the pigmentary accumulation are precisely coterminous. Now unless the ducts themselves are the effective agents, how can such a structure secrete bile? How is the central yellow pigment to be conveyed through the marginal zone of fatty degeneration?



central cells in the direction outward. How to account for the occasional presence of bile sometimes in the central, sometimes in the marginal cells, I do not know; but the variability of its seat, as well as its frequent absence, testify, I think, against the view of the secretion of bile being an *essential* part of the function of the hepatic cells. I may remark that the seat of oily accumulation varies also as that of biliary; in the livers of Dogs I have often found it in the central parts of the lobules around the intralobular vein; this is, I think, less common than the other, and I can offer no explanation of it.

Mr. SIMON states to me, "that in perfectly normal conditions among vertebrate animals, bile, to the best of my belief, *cannot* be demonstrated to exist in the hepatic cells, and I have for a long while strongly inclined to the belief that normally it never lies within them."

Professor PAGET's testimony is to the same effect: "I quite agree with you that in the healthy livers of men the cells do not contain any coloured material, but I think I have seen their contents partially coloured yellow in other cases than those of congestion."

My belief therefore is, that *in perfectly healthy states* of the mammalian liver bile does not exist in its cells, that it is not in any case *necessarily formed* there, but that this may be always effected by the ducts. It remains then to inquire what circumstances produce biliary impletion of the cells, so that they manifestly contain bile. Congestion of the portal-hepatic capillary plexus with blood, and this chiefly of a passive kind, I am inclined to regard as one principal cause. I have frequently observed in cases of heart-disease impeding the onward current of the blood, that the cells of the liver, especially those in the centres of the lobules, were gorged with bile. It is in the central part that congestion of blood is most frequently manifest; here it commences as hepatic venous congestion of the first degree, and from hence it extends outwards towards the interlobular veins. This seems to indicate that a connection obtains between passive congestion of the blood-vessels and biliary impletion of the cells. Another, and probably not less frequent cause, especially of the slighter states, is the cessation, more or less complete, of the excretory action of the ultimate ducts, the spasm of the gall-ducts of former authors; when this occurs, the biliary matter, not being eliminated from the blood by the ultimate ducts, is carried on in the blood current, and deposited in the parenchymal cells, thus producing jaundice of the liver, which, as VIRCHOW remarks, must precede jaundice of the body when this is of hepatic origin. Biliary matter may also collect in the cells no doubt, when a larger quantity of it than natural is present in the mass of circulating blood, whether this depend on insufficient oxygenation in consequence of a sedentary life and rich feeding, or on certain atmospheric influences; in this case the excess which the excretory ducts are unable to carry off passes on, and is deposited in the parenchyma. I think that the accumulation of a large amount of oil in the hepatic cells does not generally coincide with the existence of bile in them, and *vice versa*; thus in the fatty liver of phthisis

and of fish there is scarce any trace of bile to be discerned, while in the follicular liver of Mollusca the dark biliary matter very greatly preponderates over the oily; sometimes, as has been mentioned, we see different parts of the lobules the seat of oil and bile respectively; and this is most usually the case, though there is no doubt that the two products may coexist in the same cell\*.

The exact relation which the smaller and terminal ducts bear to the parenchyma is the present "vexata quæstio," and any observations that tend to elucidate this matter, and render it more easily determined, are worth our attention. I have made many examinations since the publication of my last paper relative to this point, and have been by them decidedly confirmed in the views there expressed. I stated that I believed the ducts did not ramify extensively, did not extend far beyond the "spaces," and that many fissures seemed quite destitute of them. This is, I think, generally the case, but in some instances the ducts seem to extend farther than others; with regard, however, to the main point, that the cells are a *parenchyma*, and not an *epithelium*, I entertain no doubt whatever. In many, if not in all London dogs, and in some rabbits, there is found a peculiar condition of the epithelium of the whole excretory apparatus of the liver, which renders it comparatively easy to trace and follow the ducts to their terminations. If thin sections be made of such livers, the ducts are seen as opaque tubes or tracts, appearing whitish by direct light, which come up from below at the "spaces," where three lobules adjoin, divide irregularly, and run for a varying distance along the fissures. These tubes run often a long distance without branching; they are most often single, one only traversing each portal canal or fissure, and what is especially remarkable, not maintaining any close relation to the wall of parenchyma, between which and them a distinct interval is often to be seen.

Their mode of termination varies; sometimes they break up into a few delicate branches, which may give the appearance of a plexus; sometimes they terminate by apparently losing themselves, that is to say, they gradually cease, their structure being indiscernible beyond a certain point, or breaking up into a mere streak of oily molecules. Generally I think the ducts, as seen in these specimens, are confined to the canals and fissures, but minute branches are often seen which just enter their substance for a little way: I have never observed anything that in the least indicated that the ducts formed a plexus containing the cells in anastomosing tubes as described by Dr. LEIDY. The opacity which renders the excretory ducts thus unusually distinct, is occasioned by a deposit of minute oil-molecules between the nuclei which intercept the light; this oily matter replacing in part the ordinary granular basis substance, and representing the oily matter which occurs so abundantly in the cortical renal tubuli of all London cats.

\* I request the reader to bear in mind that Mr. LINDSAY BLYTH'S experiments subjoined to this paper have fully shown that yellow pigment in the cells is not, at least commonly, any proof of the presence of true bile. The above was written before his experiments were performed.

It is perfectly clear that in neither of these cases it interferes in the least with the healthy discharge of the function, and we may learn therefore that excess alone of oil in any part does not constitute "fatty degeneration." The epithelial particles of the gall-bladder in these cases are loaded with oily molecules; they easily break up, and give exit to it very soon after death. No such oily accumulation occurs, at least necessarily, in the parenchymal cells; a further confirmation of the opinion above stated, that these cells are not, *quoad* position, a continuation of the epithelium of the ducts.

In some Human livers I have recently observed the ultimate ducts in a very satisfactory manner, and believe, on the whole, that the mode I am about to mention is the best for obtaining a view of their course and relations. A very thin section of the liver must be made at one or two lines depth from the surface; this is to be treated with acetic acid, and moderately compressed; if the liver be tolerably free from oily matter it will now become much more transparent, and on careful examination of the portal canals, spaces and fissures, some ducts will be found, and their course may be traced. It is manifest that in this way of proceeding the ducts are examined *in situ*; and if the observer have previously acquainted himself with their appearance by dissecting them out as they lie in the Glissonian sheaths, he will have no difficulty in recognizing them and following them, though he may have much difficulty in convincing himself of their actual mode of termination. Their termination by distinctly closed extremities I have certainly observed, as well as the slight amount of ramification they present, and the little intimate relation they appear to hold to the walls of parenchyma between which they run. In many fissures not a trace of them can be seen; and in those where they exist it is manifestly impossible that they can come into relation with any more than a very small portion of the parenchyma. How then, if all the cells secrete bile, could this make its way into the ducts? The ducts as they run in the fissures and canals are in the closest relation to the portal vein branch, and surrounded by the terminal plexus of the hepatic artery; so delicate, so truly homogeneous is the tunic of the vein, that it seems to me scarce possible but that the ducts in the smallest portal canal and fissures should be bathed in plasma exuding from it; from the plexus of slender capillaries, in which the hepatic arterioles terminate, they must also receive part of their supply; and lastly, when the secretion of the marginal cells of the lobules is abundant, or when the liver, as in fish, is a mass of oil, they must be bathed in this fluid.

In considering what is probably the function of the parenchyma, *i. e.* of the chief mass of the liver, we may with advantage enumerate *seriatim*, the chief points which may be regarded as pretty well ascertained respecting it. (1.) It consists, at least in Mammalia, of cells, which as long as they retain their active power exhibit nuclei; these nuclei are imbedded in a soft homogeneous granulous substance which very commonly contains oil-drops, and sometimes biliary molecules, or is tinted with bilious fluid; an envelope much more distinct than in most other glandular cells surrounds the whole particle, and seems to denote a certain amount of permanency

in its structure. (2.) These cells are very often arranged in tolerably perfect rows radiating from the centres of the lobules, but this disposition is often exchanged for a plexiform or quite irregular one. (3.) The marginal cells of the lobules, *i. e.* the ends of the rows, are especially prone to be the seat of oily accumulation. (4.) There is no arrangement of the cells comparable to those of the renal tubuli; they form rows, but not in any way the parietes of a tubular passage. (5.) There is no basement membrane to be seen in the lobules, the cells therefore lie in the closest relation to the blood in the capillaries. (6.) Young cells are frequently seen forming in the parenchyma, by collection of granulous matter round free nuclei; these do not seem to form at any particular part more than at another; they are not found solely in the centres of the lobules, *i. e.* at the commencements of the series. (7.) The cells\* have in many animals a great affinity for oil, and appropriate it so as to gorge themselves when it exists in any quantity in the blood. (8.) Sugar must doubtless also exist in the cells, as they constitute a far greater part of the parenchyma than the diffused granulous plasma; according to some observations I have made its amount is in inverse ratio to that of the oil present, for in fatty livers of foetal animals, fish, and diseased persons, I have failed to detect by TROMMER'S test the presence of sugar, which in healthy ones is always abundantly manifest. (9.) Bile, or at least the colouring principle of bile, often occurs in the cells, especially in various diseased conditions, but is not proved to exist in perfectly normal states. It thus appears that the hepatic cells differ in several particulars from the cells of other glands; they are more perfectly formed, of more permanent aspect; they are not disposed as a lining to tubes of homogeneous membrane, but in series which tend more or less to plexiformity, and are apparently distant from any free surface open to the exterior. I consider them, therefore, to form a *parenchyma* and not an *epithelium*. Their peculiarly intimate relation to the blood capillaries seems to indicate, as I suggested in my former paper, that they serve as repositories for certain matters absorbed by the blood from the chyme as it passes over the intestinal surface; these matters are however, doubtless, altered by the recipient cells and converted into sugar, perhaps also into oil or biliary matter.

It is clearly proved that sugar is *made* in the liver, that it is not found in the blood entering the liver by the vena porta, but that it exists in very large quantity in the blood passing out by the hepatic vein; the substance also of the liver, the parenchyma, contains abundance of sugar, as I have repeatedly observed. These facts show that one, and probably the chief function, of the hepatic cells is to elaborate sugar from the materials intended to be employed in respiration; and that having done so, they allow this product to return into the circulating fluid, where it perhaps undergoes further changes before it terminates in carbonic acid. The parenchyma of the liver thus resembles closely a ductless gland, such as the suprarenal capsule, allowing its

\* To this the liver of a fatted pig presents a remarkable exception; its cells seem inapt to receive the oil which so accumulates in the subcutaneous tissue.

product, like it, to return to the blood from which it had been elaborated: it may also be inferred, as not improbable, that as the elaboration of sugar is certainly one purpose fulfilled by it, so it is more likely that the bile-secreting function properly belongs to another apparatus associated with it, that of the excretory biliary ducts.

Some evidence as to this question which I have sought to obtain from chemical investigation, on the whole corroborates, I think, the view above expressed. I made an alcoholic extract of portions of the liver of several animals, evaporated this on the water-bath to dryness, and employed PETTENKOFER'S test for bile. I obtained no decisive characteristic reaction, such as is described to ensue if bile or its constituents are present; a very feeble crimson tint was developed in most cases at the moment of adding the sulphuric acid, but it very quickly disappeared, and was so faint during the brief time it lasted that I cannot think it proves the presence of biliary matter; moreover, as it is quite impossible to obtain the parenchyma quite free from the minute ducts, some of them may have imparted a slight admixture of bile which was not derived from the parenchyma; or, which is perhaps unavoidable, some oleic acid may have been dissolved by the menstruum, and given, as it is said to do, a similar reaction with PETTENKOFER'S test as bile itself. Before I was aware that albuminous matter produced with sugar and sulphuric acid the same reaction as bile, I conceived that I had found certain proof of the presence of biliary matter in the cells by applying this test to a thin slice of liver and watching the changes under the microscope; under the action of the acid the tissue became much more translucent, and developed along its margin a beautiful permanent crimson tint. The very same however, even more intense, was produced by treating a section of kidney in a similar way, so that it was manifest the reaction depended on nothing special to the liver.

One other fact we may receive from chemistry, which is also corroborative of the view that the sugar and bile are not produced in the same parts, viz. that the bile does not contain the hepatic sugar. M. BERNARD distinctly states this, and on repeating the experiment I obtained the same result. Sugar therefore seems to be the normal product of the cells, bile of the ultimate biliary ducts.

Mr. NOAD has been kind enough to execute some analyses for me, which go to show that the kind of food influences decidedly the amount of sugar contained or formed in the liver. The subject of the first was a young dog, who was fed for six days on bread and meat; the quantity of sugar contained in his liver, as determined by fermentation, was 20·13 grs. per 1000. The second, a young kitten, was fed for six days on food as far as possible of the saccharine kind, rice, sugar, arrow-root and potatoes; this disordered her bowels after some days, but by leaving off the rice and confining her to potatoes chiefly she recovered her health. Her liver contained 31·66 grs. of sugar per 1000; it also was seen under the microscope to contain much oil. Another kitten of the same age was fed for about a week on bread and butter, and milk, so as to approach nearly to a diet of oily food; her liver was quite opaque from the presence of abundance of oil, much more manifestly being present than in the two others; it yielded by fermentation 21·13 grs. of sugar per 1000.

The results stand thus:—

Albuminous food per 1000 grs. of liver . . . .	20·13 grs. of sugar.
Saccharine food per 1000 grs. of liver . . . .	31·66 grs. of sugar.
Oily food per 1000 grs. of liver . . . . .	21·13 grs. of sugar.

Hence the saccharine diet produced fully one-third more sugar than the albuminous or oily. M. BERNARD however has distinctly proved that the liver forms sugar from the blood when only albuminous food is taken, so that it seems certain that a converting change must go on in the organ, which is exerted not only upon saccharine, but also upon albuminous and probably upon oily matters. One of the results of this converting change may sometimes be biliary matter, which would then appear in the cells, as we have seen that it occasionally does; but in the majority of cases observation seems to testify that sugar and oil are the products or results of the energy of the hepatic cells.

I would for a moment refer again to a point noticed in my previous paper, viz. *that at the moment when the liver traced in the ascending animal series assumes a solid parenchymal form, it receives a portal vein which is distributed exclusively to the parenchyma*: this at once seems to imply a special relation between the two, that the one is developed for the sake of the other, and that their functions are coordinate. A portal vein is not needed for the secretion of bile; this product is most copiously formed in the follicular livers of Mollusca, which are supplied by an hepatic artery only; and it therefore is extremely probable that the parenchyma is added for some further and different purpose; this purpose being, as I have suggested, the temporary abstraction from the blood of such matters as being absorbed in considerable quantity from the intestinal surface could not, without disturbing too far the due crasis of the blood, be immediately poured into it. It is impossible to conceive a structure better fitted to fulfil this purpose than the lobules of the liver, which are percolated from their circumference to their centre by capillary blood streams.

The function of the parenchyma I believe, then, to consist chiefly in exerting a modifying action on the portal blood and preparing a product which enters the circulation, and is probably consumed in the service of respiration. The presence of much oil in the cells seems chiefly to depend on the existence of an unusual amount in the blood, which may be occasioned by various causes; thus the fatty liver of fish and of the fœtus seems connected with a low degree of respiration; that of phthisis partly with increased absorption of fat, partly with diminished respiration; that of sheep fed on oil-cake with the oily nature of the food. To three of these cases certainly, if not to all, the term fatty degeneration is quite inapplicable; the condition is that simply of oily accumulation.

The function of the excretory ducts, if my description of their relations is correct, is not merely that of conveying forth out of the organ a product already formed; they must act upon certain matters supplied to them with an energy of their own, and out of these elaborate their secretion themselves. It may be said generally that

the ducts which present the structural characters that appear indicative of an active function, *i. e.* those which approach their termination, are in contact with parenchymal cells and celloid particles containing varying quantities of sugar, albumen and oil; they are also surrounded by the rather scanty plexus of the terminal twigs of the hepatic artery, and moreover they run in such close relation with the delicate walled portal vein branches that they may possibly receive plasma exuded from them. In fishes' livers, where the quantity of fibrous tissue is small, it is very remarkable to observe how the ducts are encrusted with the oily parenchyma, as it were bathed in its fluid; in this instance it is impossible to avoid the idea that this abundant oil serves to the ducts as a plasma, *out of which*, by means of their epithelium, they elaborate bile. The same must hold in cases of fatty liver in higher animals; and generally it seems probable that the parenchyma furnishes a suitable fluid (which may often be in part already of biliary nature) which the ultimate ducts employ in their eliminative action.

Now have we any evidence tending to show that an active change is taking place in the ultimate ducts,—that they are more than mere efferent channels? Such I think has been already detailed, and I will refer to it here again.

The presence of abundant granulous matter in the ultimate ducts of fishes' livers speaks in favour of an active change proceeding in these parts, as also do the pellucid vesicles, which often crowd together so closely in them; such surely would not be found in a mere efferent canal. Compare the condition of the epithelium of the cortical renal tubuli of those in the medullary cones as an illustrative instance; in the first, the nuclei, surrounded with abundant granulous matter, constitute celloid particles and sometimes cells; in the other, the nuclei lie applied against the limitary wall almost naked and alone. Manifestly the one is a secreting part, the other a mere channel of exit. In Reptiles and Birds the case is the same; the ultimate ducts are not lined by small epithelial particles, but well nigh filled with vesicles or granulous matter, which must be supposed to be continually breaking up into the fluid secretion and some complementary matter. In Mammalia we meet ordinarily with a seemingly different condition of the ultimate ducts, which, though rare, also occurs in Fishes and Reptiles. The nuclei are not buried in granulous matter, but are set as it were in a thin layer of it, and leave a distinct central channel between the opposite walls; yet they are not formed into distinct particles; there are no columnar cells like those of the larger ducts; the nuclei abide in all their separate entirety. Have we knowledge of any secretory structure similar to this, with which we may compare it, and which may aid us to comprehend it better? Such a one is found in the cavities of the thyroid, where the epithelial layer, precisely similar in constitution to the walls of the ultimate biliary ducts, rests externally upon the limitary membrane, and internally is in contact with the secretion it has elaborated. Can we interpret the import of this arrangement? Can we perceive its peculiar significance? It seems scarcely doubtful that the more perfect a cell is the greater is its permanence; a

celloid particle may rapidly decay, but a cell with a well-marked envelope is destined to a longer life; its contents are as it were locked up. In such cells too, when the secretory act is ended, the nucleus disappears, and the cell is henceforth only a repository of the product. This type of secretory action is, compared to the other, gradual and slow. But if a nucleus remain as such, if it exert an unceasing energy, or at least retain the power to exert that energy at intervals, if instead of developing a single cell, filling it with secretion, and then perishing, it continue to attract, to change and to repel charged matter, then we have a structure which is adapted for continuous, and, it may be, rapid action. This we have much reason to believe is the case in the instances of the thyroid and of the biliary ducts.

I might also refer to the case of the intestinal villi during absorption, which is a rapid and temporary process; the nuclei seem to attract the chyle into the villus; they do not develop cells wherein to enclose it, but allow it straightway to flow off by the lacteals, while themselves unchanged continue to attract fresh matter.

I believe then the two conditions of the ultimate ducts to be essentially similar, differing only in the more or less quantity of granulous matter, by whose disintegration in each case the material of the secretion is furnished; the presence of the vesicles in the ducts so often mentioned, seems to me strongly indicative of active growth, though less rapid, and by consequence of change and decay; and thus corroborates decidedly the view I have expressed.

Once I have seen the nuclei of the ultimate ducts deeply bile-tinged; this was in the liver of a Squirrel (*Sciurus*), where many of the parenchymal cells also contained bile; this also seems to indicate an attractive power resident in them; it was remarkable that some ducts were not thus coloured, and in these the nuclei were less elongated, were plumper, more healthy and vigorous-looking, to use a metaphorical expression. The gall-bladder was nearly empty, and the condition, I suppose, was one of sluggish action of the ducts; hence impletion of some of the parenchymal cells with bile, and staining of the nuclei of the ducts with secretion not thrown off. Those unstained were doubtless efficient and active.

---

As it appeared to be matter of great importance to ascertain whether the parenchyma of the liver really contained bile, that is, not only the colouring matter of the secretion, but its organic salts also, I applied to my friend Mr. LINDSEY BLYTH, who most kindly undertook at my suggestion a series of experiments to endeavour to decide the question. I may remark, that in the case of the liver there is far more reason to expect that its secretion should be capable of being detected in its substance, than there is in that of the kidney; urea cannot be found in the renal parenchyma, probably because it is so rapidly and completely carried out of the tubes of which it consists, and which present only an extremely thin layer of epithelium to be traversed in its transit from the blood into their cavity. But in the liver, the bile, if it exist



in the cells, has no ready means of escape ; it must traverse a long series before it can be received into the ducts, and those who affirm that it exists in the cells, point to the yellow matter contained visibly in their interior as proof of its presence. It is to be supposed therefore that if this yellow matter be bile it will give the characteristic reaction of this fluid.

### *Experiments.*

(1.) Healthy Sheep's liver weighing 2 lbs. Separated the mass of the parenchyma as much as possible from the larger vessels, made a watery extract from which the albumen was separated. TROMMER's test showed the presence of sugar in abundance ; PETTENKOFER's gave no indications of bile ; evaporated the extract to perfect dryness, and then treated it with cold absolute alcohol, and then with boiling spirit, neither of which gave any indications of bile. The solutions tested were very concentrated ; the whole extract obtained from the mass of 2 lbs. weight was contained in about 1 oz. of fluid.

(2.) A portion of a Pig's liver, treated in a similar manner. Abundance of sugar was obtained, no trace of bile.

(3.) A healthy Human liver, weight 2 lbs. ; the whole parenchyma was treated in the same way as that in experiment (1). The watery extract gave abundance of sugar, no bile. The cold alcoholic solution precipitated by ether gave no indication of the presence of a salt of cholic acid.

(4.) A small piece of Human liver. The cells engorged with yellow matter ; first treated with alcohol, which on testing gave no trace of bile, but took up a beautiful deep yellow pigment and oily matter. The watery extract gave no trace either of bile or sugar, but the addition of sulphate of copper and liquor potassæ produced a beautiful azure solution, from which nothing was precipitable by heat.

The addition of a very minute portion of bile to the alcoholic solutions caused the characteristic reaction to take place with PETTENKOFER's test.

(5.) A Human liver ; the subject a strong healthy man, who died from a fracture of the thigh ; it presented a healthy appearance. No trace of sugar or bile was found in it. The patient had partaken of no food for two days previous to death, excepting a small quantity of beef-tea from time to time.

(6.) A portion of Human liver, of decided yellow tint, the cells generally gorged with oil, some containing yellow matter. The man died from the shock of an accident, which caused fracture of the pelvis. The ethereal extract gave a liquid oily product, on which nitric acid produced a play of colours, but no trace of cholic acid was found by PETTENKOFER's test. The alcoholic extract gave a solid fat, but not of so deep a colour as the ethereal, and a very slight reaction with nitric acid. No trace of cholic acid was found in it. The watery extract gave no trace of sugar or bile. Potash and copper being added gave a dirty brown solution, from which nothing was thrown down by heat or was deposited after standing.

(7.) A piece of Human liver of healthy appearance, but the cells around the intra-lobular veins contain a great deal of deep reddish yellow matter. Four extracts were made. 1st. Chloroform gave a beautiful crystalline residue of solid fat, partly coloured with yellow spots. PETTENKOFER'S test gave no trace of cholic acid; nitric acid gave a very slight purple tinge, which changed into green. 2nd. Ether gave an abundant deposit of oils and fats which produced a slight reaction with nitric acid, but no trace of cholic acid with sugar and sulphuric acid. 3rd. Alcohol gave a coloured extract containing fatty matters, more solid than those from ether, but showing on being tested no trace of cholic acid. 4th. Water; the extract gave no trace of cholic acid, but on the addition of liquor potassæ and sulphate of copper, a portion of the copper was reduced by boiling to the red oxide, and the supernatant liquor remained of a beautiful azure tint, in which no change was effected by heat on long standing. This azure colour, as in (4), probably indicates the presence of glyocol, which is united with cholic to form the glycocholic acid of the bile. The fatty matter saponified by potash and extracted with alcohol gave no trace of cholic acid.

(8.) A cat's liver; the animal had been treated with calomel, and had taken twelve grains in twenty hours. The aqueous extract gave some trace of sugar and of fat, but none of cholic acid.

(9.) Liver of a man who died with suppuration in all the divisions of the portal vein, the smaller branches being blocked up. The interior cells of the lobules were filled with yellow matter. The aqueous solution of the parenchyma gave no indication of cholic acid or sugar, but with TROMMER'S test a solution of fine blue colour was obtained, from which nothing fell down on boiling or after long standing. This seems to indicate the presence of glyocol. The gall-bladder was inflamed; its contents gave no reaction of cholic acid or sugar.

(10.) Liver of a female extremely fat; died with tubercular cavities in lungs. The presence of sugar and probably of glyocol was ascertained by TROMMER'S test. The contents of the gall-bladder were thick and of a dark saffron colour; contained very little cholic acid, no sugar, a great deal of colouring matter.

(11.) Liver of a patient who died from inanition ten days after having cut his throat; it gave no trace of sugar nor of glyocol.

(12.) Liver of a distinct yellow colour, extremely fatty, the cells gorged with oil, and containing much yellow matter also. The aqueous solution gave a deposit of suboxide of copper with TROMMER'S test, and the supernatant liquor remained of a purple colour, thus indicating the presence of sugar and glycine. The alcoholic solution gave a beautiful reaction with nitric acid (first green and then purple), characteristic of the colouring matter of the bile, but no trace of cholic acid; it contained also a small quantity of fatty matter. The female from whom this liver was taken, was jaundiced at the time of her death.

The conclusions which may be drawn from the foregoing observations are—

(1.) That sugar, bile-pigment, and probably glyocol, can be detected in the hepatic cells. (2.) That cholic acid cannot be detected in them, and that therefore it is not necessarily united with the bile-pigment. (3.) That after abstinence from food sugar disappears from the liver. If these conclusions be admitted, it is clear that the hepatic cells do not form perfect bile; they form sugar, and two of the biliary principles, but not the organic acid, which is probably the most important.

## EXPLANATION OF THE PLATE.

## PLATE I.

- Fig. 1. Ducts containing vesicles imbedded in pellucid and amorphous matter; they are such as I believe to have an *active* function. Diameter =  $\frac{1}{1000}$ th of an inch.
- Fig. 2. Gall-bladder, cystic, hepatic and common ducts in a very young fish, together with the intestine: the hepatic ducts appear as rudimentary developments from the cystic.
- Fig. 3. (a) An ultimate duct, with closed extremity, consisting of nuclei set in a sub-granular basis substance from liver of Frog.
- (b) (b) Two ducts containing the vesicular epithelium from a different part of same liver. The diameter of these two was, that of the larger  $\frac{1}{714}$ th of an inch, that of the smaller  $\frac{1}{833}$ rd of an inch. The duct (a) had a diameter of  $\frac{1}{1250}$ th of an inch.
- (c) Duct from a young rabbit, dosed with blue pill; it contains very numerous delicate vesicles with interposed oily molecules. Its diameter =  $\frac{1}{1000}$ th of an inch, that of the vesicles =  $\frac{1}{2500}$ th of an inch.
- Fig. 4. Alimentary canal and liver of Tadpole, with gall-bladder and rudiment of duct. *s*, indicates the stomach; *t*, the throat; *i*, the commencement of the intestine; *ll*, the two lobes of the liver; *g*, the gall-bladder, lined by a vesicular epithelium; *d*, the rudiment of the cystic duct. The liver consists of mere formative yolk matter; the duct seemed to consist of similar substance but more opaque; it was not hollow; its margin was very defined. The gall-bladder measured  $\frac{1}{63}$ rd of an inch in diameter; its cavity was filled by a clear fluid.
- Fig. 5. (A.) A terminal duct from the liver of a Guinea Pig; it had a most distinct closed extremity; its diameter =  $\frac{1}{1000}$ th of an inch, that of its canal =  $\frac{1}{4000}$ th of an inch. It was seen lying along the wall of a tolerably sized portal canal. Some of the parenchymal cells are represented.
- (B.) Ducts from Squirrel's liver; one is seen lying on the homogeneous tunic of a blood-vessel (a portal vein branch); its extremity was even, and was probably terminal; its nuclei were bile-tinged. The other duct has very

distinct nuclei, which appear plump, and are not bile-tinged; its amorphous substance also is paler. A parenchymal cell, about  $\frac{1}{1000}$ th of an inch in diameter, is figured. The two ducts had each a diameter of  $\frac{1}{2500}$ th of an inch.

Fig. 6. View of a portal canal and portions of the two parietal lobules, with an ultimate duct running in the space nearer one side than the other. The duct is single; no other existed in this part; it gave off no branches, and had no communication (visible at least) with the lobules. The diameter of the portal canal was  $\frac{1}{333}$ rd of an inch, that of the duct  $\frac{1}{1100}$ th of an inch. The specimen was taken from a dog, in whom the epithelium of the gall-bladder and the ducts was in the oily condition described in the text. The larger ducts had a distinct homogeneous tunic, the smaller no perceptible one, but consisted of groups of minute oily molecules, which formed at last mere streaks; a distinct closed rounded extremity was not observed.

Fig. 7. View of one of the glands of the large hepatic duct-trunks in the liver of a Dog; it belongs to the conglomerate type: its cavities were *filled* with an opaque granulous matter containing numerous oil-drops, as well as many nuclei. Some of the contents are figured on the side.

Fig. 1.

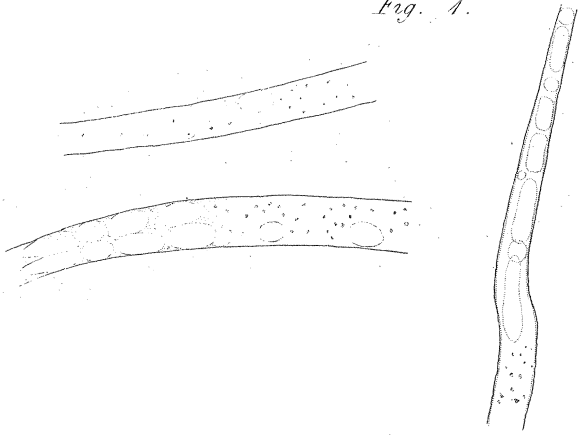


Fig. 2.

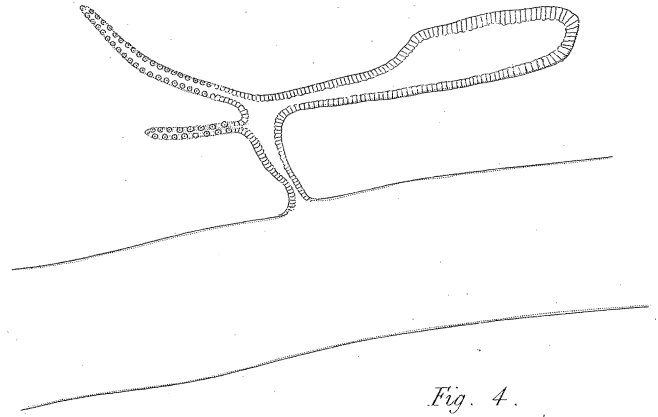


Fig. 3.

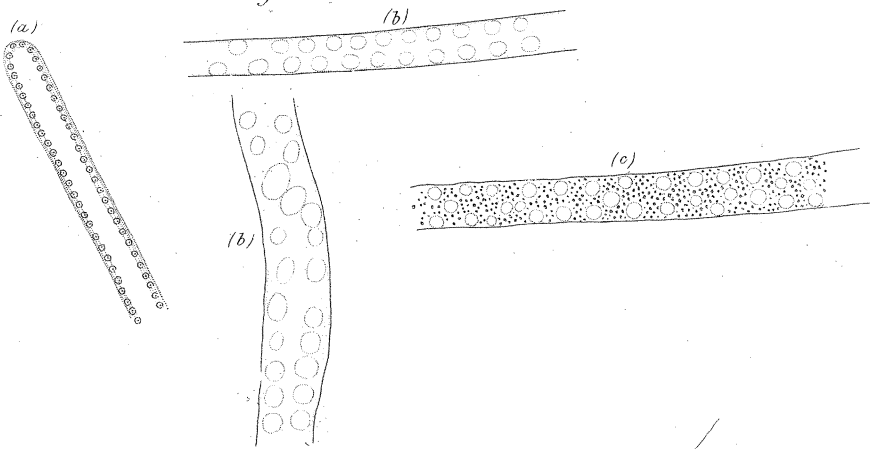


Fig. 4.

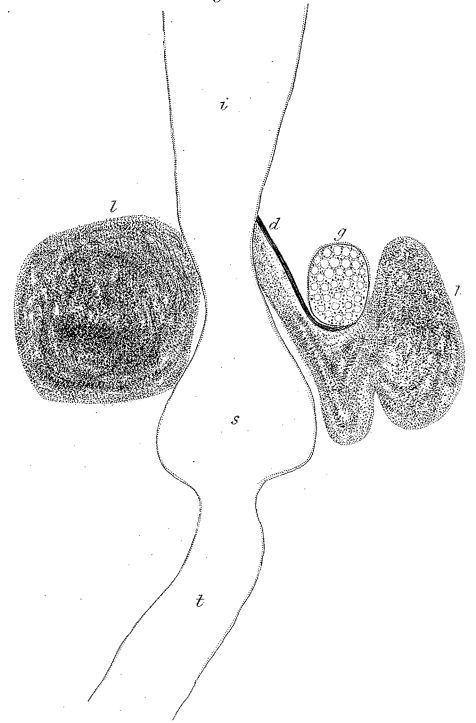


Fig. 5.

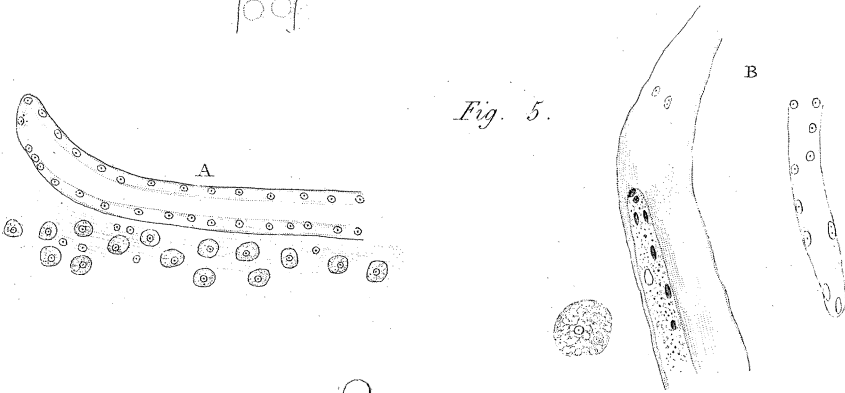


Fig. 6.

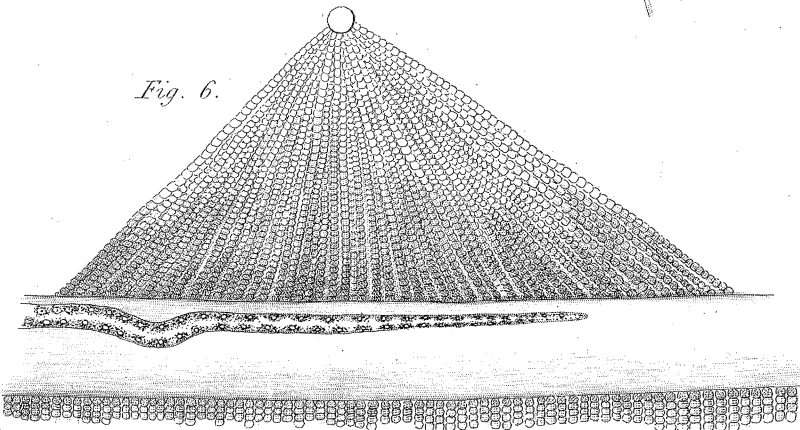


Fig. 7.

